

Original article**Quality Evaluation and Detection of Formalin in Market Milk in Khartoum State (Sudan)**

^{1,3}Shama, I. Y. Adam*, ²NesreenAlsanousi.,¹Mohammad,O. Adam., ¹Rashida, E. Murgani., ¹Samar, S. Abdolrahim.,¹Asma, M. Yousif and Abdel Karim Sabir Ali⁴

¹Department of Biochemistry and Molecular Biology, Faculty of Science and Technology, Al Neelain, University, Khartoum, Sudan. ²Biotechnology Research Center, Al Neelain University, Khartoum, Sudan. Neelain Institute for Engineering, Technology and Compute Researches. ⁴Department of Environmental Sciences, Faculty of Science and Technology, Al Neelain University.³Department of Environmental Sciences Faculty of Science and Technology, Al Neelain University, Khartoum Sudan

ARTICLE INFO**Article history:**

Received 2020 January 27th

Reviewed 2020 May 3rd

Accepted 2021 May 29th

Keywords:

Food preservatives, Formaldehyde, Milk, Toxicity, Wister rats

Abstract

Background and objective: Food spoilage is a common problem, and the use of chemical substances could delay the spoilage. Some traders add formalin to milk as a preservative. This study was aimed to test the presence of formalin and its preservation effect on milk sold in the markets of Khartoum state. Also, to evaluate the toxic effects of formalin abuse in Wister Rats.

Materials and Methods: Random Milk samples were collected from three localities of Khartoum and tested for the presence of formalin. Fresh milk samples were collected in five sterile utensils and different concentration of formalin (.5, 1, 2,3and 5ml/L) were added and the samples stored at room temperature in order to study the relationship between the concentration of formalin and milk keeping time. For the formalin toxicity study, three-month-old 16 Wister rats divided into four groups each of four rats, 3 groups received different doses of formalin (1,3,5 ml /L / kg) for 3 weeks and group 1 serve as control group. The experiment lasts for 21 days and then rats were euthanized; blood samples and liver sections collected, serobiochemical and hematological parameters were recorded.

Results: The results confirmed the use of formalin in Khartoum (70-75%) of the total tested samples. The addition of formalin keeps the milk fresh for 21 days. Toxicity study showed that formalin lead to significant elevation on liver enzymes on serum of rats, there was insignificant difference in mean concentration of urea and creatinine in groups received formalin with low, medium and high dose with p-value (0.8, 0.6, 0.5) and (0.5, 0.5, 0.7) respectively versus control group. Also, there was insignificant difference in body weight of groups treated with formalin versus control group. Formalin offered non-significant change on WBC, MCV, MCH, MCHC (p>0.05), and significant change on RBC, HG, HCT and Platelets (P<0.05). There were also increases in concentrations of serum phosphorus and calcium.

Conclusion: Formalin is an extreme preservative, very toxic and dangerous; it shouldn't be used for preservation of milk that meant for human consumption. Therefore, we strongly recommend the ban of formalin to the common uses in milk preservation.

* Corresponding author E- mail: shamaadam@hotmail.com

Introduction

Milk in its natural form has a high food value, since it is comprised of a wide variety of nutrients which are essential for proper growth and maintenance of the human body. Early-

lactation milk contains colostrum, which carries the mother's antibodies to its young and can reduce the risk of many diseases. Milk contains many other nutrients such as protein, lipid, carbohydrate, vitamins, minerals, enzyme, and most important nutrients required by the body (Pehrsson *et*

al., 2000 ; Rolf Jost, 2007). In Sudan milk is produced for local consumption and it's an important component of the diet. In some parts in Sudan cattle keeping considered a n important economic activity and the access to market is a big challenge for cattle keepers.

In many countries, milk come from areas that are generally far away from the dairy farming communities, this problem aggravated by the need for facilities to keep the milk cool in order to minimize bacterial proliferation. Some physical methods have been used to preserve the milk and to keep it fresh for long period of time such as pasteurization, dehydration and refrigeration. Another alternative way is to preserve milk with chemical preservatives and artificial preservatives (Saha *et al.*, 2003). Recently scientists have used various milk preservatives (hydrogen peroxide, sodium azide, bronopol, potassium dichromate, formalin, boric acid, *Milkofix*, azidiol, ortobor acid), and antibiotics such as penicillin to overcome the spoilage problem. The problem is that, chemicals being used may have a negative effect on human health and milk that contains these preservatives is not meant for human consumption (Kate *et al.*, 2009; Seškēna and Jankevic, 2007).

Formalin is the formaldehyde solution, and primary used as a preservative of biological samples. Formalin is highly toxic to humans in small amounts and is classified as a carcinogen (James *et al.*, 2013). Its ingestion is known to induce acute poisoning, causing disorders in the oral cavity and irritation, often leading to dry skin, dermatitis, headaches, dizziness, tearing eyes, sneezing and coughing, and even the development of allergic asthma. Accidental exposure to formalin is common as an occupational hazard. Exposure to large amounts has been linked to, nasal and pharyngeal diseases, laryngospasm, and pulmonary edema, though these health effects are unlikely with the concentrations present in milk (Tang *et al.*, 2009; Gwin *et al.*, 2010). Chronic inhalation of formaldehyde may cause hepatotoxicity and nephrotoxicity (Sadyekum *et al.*, 2010 ; Mamun *et al.*, 2014). The IARC (2012) discussed the evidence for formaldehyde causing three types of human cancer: nasopharyngeal cancer, sinonasal

cancer and leukemia (European Food Safety Authority, 2014)

Milk is a widely consumed beverage that is essential to the diet of several millions of people worldwide because it provides important macro- and micronutrients. Chemical preservatives are commonly used; this may have a great impact in human health.

This study was aimed to test the degree of presence of formalin in milk samples in Khartoum state and to evaluate the formalin effect on milk and investigate the potential adverse health effects associated with the consumption of milk preserved with formalin.

Materials and Methods

This study was conducted in Al Neelain University, Khartoum State - Sudan during the period from March to June 2018.

Samples

The milk samples were collected randomly in period from Khartoum State. The total 105 sample (34 from Omdurman, 33 from bahri and 33 from Khartoum locality), collected in sterile containers and stored in -4° until the analysis. Five samples collected immediately from the Cow's in a farm and used as control samples.

The Formalin (37% formaldehyde), utilized in this study was provided by the Biochemistry Laboratory -Faculty of Sciences and Technology, Al-Neelain University, Khartoum, Sudan.

Animals

Sixteen- both sexes Wistar rats with average body weight ranged from 100 -130g, were used in this study. The rats were clinically healthy and housed within the premises of Faculty of Science and Technology-Al-Neelain University animal house under standard husbandry conditions, (30°C ± 2°C, 60–70% relative humidity and 12h: 12h day-night cycle) and fed on the rat diet and drinking water provided *ad libitum*. Animals were acclimatized to the experimental conditions for a period of one week prior to the commencement of the experiment.

Methods

Detection of formalin in milk

10 ml of milk measured in a test tube. 5 ml of concentrated Sulphur acid were added to the milk through the sides of the test tube without shaking. The appearance of violent ring indicates the presence of formalin in the milk sample (Singh *et al.*, 2012).

Testing the duration of preservation of milk

Samples of Cow's milk was collected in sterile containers from local farms and arias and tested for the presence of Formalin, taking 1000 ml of Cow's milk in sterile containers, 5 samples. Different concentrations (0.5 ml, (1) ml, (3) ml and (5) ml of formalin was added to five samples of milk separately to test the duration of preservation of milk.

Toxicity study experimental design

The rats were divided randomly to 4 groups, each of 4 rats. Group 1 continued to be fed the normal diet and served as control (only distilled water daily for 21 days). Groups 2, 3 and 4 were given 1ml formalin at 1, 3 and 5ml/L/kg/day orally through cathedral tube, respectively. All rats were dosed their designated experimental oral doses for 21 days. Body weights of rats were measured on day 0, 7, 15th and day 21th of the treatment. Blood samples for biochemical parameters were taken at the end of the experiment after scarifying animals under mild chloroform anesthesia.

Hematological analysis

Whole blood for measurement of complete blood count (CBC) collected in EDTA anticoagulant blood containers, and the measuring techniques were performed according to an automated heamatology analyzer (Human GambH, Max-planck- Ring 21, D-65205 Wiesbaden, Germany). Hemoglobin (Hb), packed cell volume (PCV), red blood cells (RBCs), white blood cells (WBCs), differential WBC counts and erythrocyte series, mean corpuscular volume (MCV), mean corpuscular hemoglobin (MCH), and mean corpuscular hemoglobin concentration MCHC were determined.

Biochemical analysis

Blood samples for serum chemistry were collected and

allowed to clot and serum were separated by centrifugation at 3000 *rpm* for 5 min and stored at -20C until analyzed. Serum samples were analyzed for the activities of aspartate transaminase (AST), alanine transaminase (ALT) and alkaline phosphatase (ALP) and for concentrations of urea, creatinine, calcium and phosphorus using commercially available kits ((Biosystem chemicals, Barcelona,spain).

Statistical Analysis:

Statistical Package for Social Science (SPSS, version 16) was used for the analysis of the data. The values have been analyzed by one-way analysis of variance (ANOVA) followed by Duncan's simple T-test. The significance of differences between means (mean \pm Standard error (M \pm S.E)) was compared at each for all groups. P<0.05 was considered statistically significant (Snedecor and Cochran, 1989).

Results

Detection of formalin in milk

All milk samples were tested for the presence of formalin and the experimental results of formalin detection are presented in (Fig 1, 2). The result of test shows that over 70% of the milk samples tested positive for formalin. In Khartoum, 69.70% of tested samples showed positive result for the presence of formalin, in Bahri 75% of samples were positive, and in Omdurman 70.50% of the samples were positive for the presence of formalin. Comparative for the presence of formalin (%) in Cow's milk in all groups are presented in (Fig 3).




Fig. 1. Positive results of detection of formalin in milk. (Violet ring).

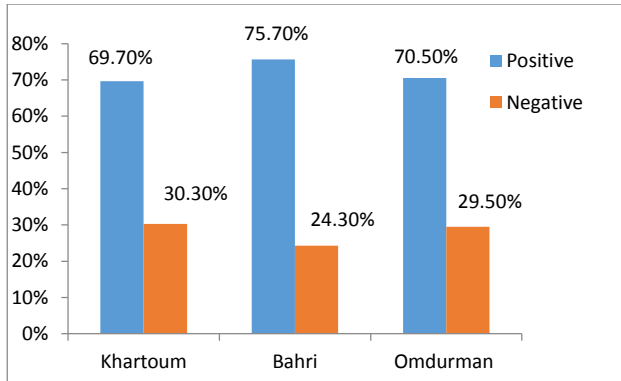


Fig. 2. Comparative for the presence of formalin (%) in Cow's milk samples collected randomly from Khartoum, Bahri and Omdurman. (n=100).

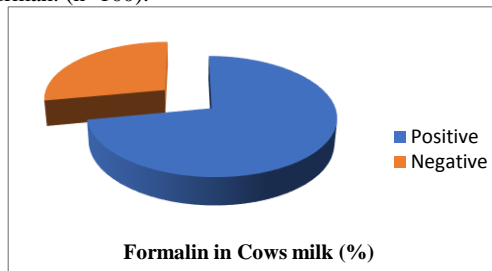


Fig. 3. The results of formalin (%) in Cow's milk showed that, out of 100 samples 72% were Positive and 28% were Negative.

Formalin effects of milk

The study was conducted over a period of three weeks. The obtained results indicate the efficiency of adding formalin to Milk for preservation. There was no change in the characteristics of milk samples during the experimental period (Table 1 and Fig 4).

Table 1. Effects of different concentrations of formalin on after 3 weeks.

Concentrations of formalin in milk	Observed effects
1. 0.5 ml/L	- ve
2. 1 ml/L	- ve
3. 2 ml/L	- ve
4. 3 ml/L	- ve
5. 5 ml/L	- ve

(-ve) = no change in milk characteristics




Fig.4. Negative result of detection of formalin in milk

Growth changes

After 3 week's administration of Formalin, results showed significant decrease in the weight of the treated groups (group 2 after one week and group 4 after 3 weeks) compared to the control (group 1). The body weight in groups 3 and 4 after one week and groups 2 and 3 after 3 weeks were increased compared to control, while group 4 after 3 and 4 weeks showed no significant changes. The data of the changes in the body weight are represented in table 2. No death among the rats occurred.

Hematological changes

Hematological parameters (Hb, PCV, RBCs, WBCs, differential WBCs, MCV, MCH and MCHC), of rats treated with 1, 3 and 5ml/L/kg/day of formalin was showed in table 3.

After 4 weeks of the treatment of the rats with their designated dose with the formalin, no significant changes were observed for all the measured parameters (WBC, MCV, MCH, MCHC) (P<0.05), and significant change on RBC, Hb, PCV and Platelets (P<0.05) were observed, compared to normal control (group1).

Serobiochemical changes

Serobiochemical data are summarized in table 4. The AST and ALT activity after 4 weeks of the treatment of the rats with their designated dose with the formalin in all groups were significant increase. There were no significant differences in the concentration of urea and creatinine in treated groups compared to control. The activity of ALP increased in group 4 and decreased in groups 2 and 3 compared to control (group 1). The concentration of

Phosphorus and Ca^{+2} were significantly increased in all groups, compared to the control (group 1).

Table.2. Body weight and Body weight gain for rats given formalin different doses orally compared with control for 3 weeks.

Treatment groups	Body weight (g) 0 day	Body weight gain (g) one week	Body weight gain (g) two weeks	Body weight gain (g) three weeks
1.Control (untreated)	133.0±10.5	4.0±11.1	4.0±11.7	9.5±12.4
2.Low dose (1ml /L)	129.5±10.5	1.0± 9.1 *	5.5±10.7*	5.4±12.4*
3.Medium dose (3ml /L)	130.8±10.5	6.3±10.1*	7.8±11.0*	1.0±12.4*
4.High dose (5ml /L)	131.5±10.5	6.5±10.4*	3.0±11.7 ^{NS}	11.0±12.4 ^{NS}

Values are mean ± SE; NS: Not significant; *: Significant: (p>0.05).

Table 3: Hematological changes in rats given formalin for three weeks

Parameters	Control (untreated)	Low dose (1%)	Medium dose (3%)	High dose (5%)
WBCs($\times 10^3\text{mm}^3$)	14.6±8.6	12.7±1.8 ^{NS}	13.7±3.68 ^{NS}	15±3.4 ^{NS}
RBCs($\times 10^6\text{mm}^3$)	6.25±.43	6.6±.68 ^{NS}	8.3±.17*	6.1±.7*
Hb(g/dl)	11.1±1.17	12.6±.65*	14.5±.56*	10.17±.9*
PCV (%)	35.1±1.2	40±2.1*	45±.7*	36±.3*
MCV(m^3)	56.4±2.4	60.7±3.2*	54.9±.8 ^{NS}	59.3±3.2 ^{NS}
MCH (pg)	17.7±.66	19.1±.1 ^{NS}	17.5±.47 ^{NS}	18.4±1.5 ^{NS}
MCHC (%)	31.4±.8	31.5±.1 ^{NS}	31.9±.45 ^{NS}	31±1.8 ^{NS}
PLT ($\times 10^3\text{mm}^3$)	2.78±.9	1.4±5.3*	1.3±1.6*	1.37±2.6*

Values are mean±SE; NS: Not significant; *: Significant: (p>0.05).

Table.4. Serobiochemicalanalysis in rats after exposure to Formalin for 3 weeks.

Parameters	Control (untreated)	Low dose (1%)	Medium dose (3%)	High dose (5%)
AST (iu)	76.0±7.7	76.5±5.2 ^{NS}	53.0±5.9*	106.0±5.8*
ALT (iu)	135.8±8.6	328.5±12.4*	333.5±12.4*	278.8±30.0*
ALP (iu)	203.0±5.3	156.0 ±7.0 *	145.0 ±15.6 *	301.8 ±10.4 *
Creatinine(mg/dl)	0.53±0.1	0.49±0.1 ^{NS}	0.58±0.1 ^{NS}	0.50±0.1 ^{NS}
Urea(mg/dl)	31.5±13.5	30.3±4.2 ^{NS}	28.8±2.2 ^{NS}	34±3.3 ^{NS}
Calcium (mg\dl)	6.1 ± 2.4	10.4 ±1.5*	8.9 ±1.2 *	9.7 ±2.13 *
Phosphorus(mg\dl)	3.1 ± 1.0	13.2 ± 16.6*	11.0 ± 8.0*	17.5 ± 9.1*

Values are expressed as mean ± SE; NS = not significant; *Significant = (P< 0.05)

Discussion

The milk is very important nutrient for young and adult. The problem of preservation of milk samples is common because markets are generally far away from the dairy farming communities; transport of the milk is inadequate. Recently, the use of formalin as a preservative of milk increased in Khartoum and this becomes a problem because of the health

risk associated with the improper formalin use. The present study aimed to investigate the abuse of formalin by milk dealers in Khartoum state and to study the duration of milk preservation with formalin and the effect of formalin abuse on Liver and kidney functions of Wistar rats.

The results of present study showed that the use of formalin as preservative for milk in Khartoum state is common and the

formalin can preserve milk for a long duration. The effects of oral doses of different concentration of formalin on Wistar rats have been investigated; emphasis was placed on comparative changes in growth, clinical abnormalities, lesions, and alterations in serobiochemical constituents of treated rats. A significant increase in ALT activity of groups treated with low, medium and high doses versus control group with (p-value 0.00) was shown. Our finding contradicts the previous result reported by Olooto who stated that, there was no significant difference of ALT activity between formalin treated groups and control (Olooto, 2010). Another study stated that serum AST and ALT were increased significantly in swiss albino mice exposed to formalin, and this in agreement with our findings. (Afrin *et al.*, 2016). As distribution of ALT enzymes in different tissues (hepatocellular, RBCs and Cardiac), increased of ALT activity may indicate damage of tissues of origin¹⁶. The results of present study provide experimental evidence that, there was significant increase in AST activity of groups (Medium and high doses) after administration of 21 days in comparison with control group with (p-value < .05). This finding agrees with Jeffery who reported that the formalin increase the activity of enzymes related to liver damage, and disagrees with Olooto in previous study which reported that, AST level was not significantly changed in the formalin treated groups. (Liu *et al.*, 2014 ; Jeffery and Koplan, 1999). The increase in AST activity indicate hepatocellular damage and/or liver cell toxicity as a result of formalin abuse. Previous experimental studies found that formalin also caused some changes in the microscopic structure of liver tissues. Beall and Ulsamer reported that exposure to formaldehyde can cause focal cellular necrosis and centrilobular vacuolization in the liver (Beall and Ulsamer, 1984; Mahmut *et al.*, 2017). Furthermore, decrease in the body weight gained in treated groups with different doses indicates that formalin may interfere with growth processes and it may cause damage to the liver. An early study concluded that degeneration and apoptosis were observed in the histological structure of liver tissues following the formalin administration (Mahmut *et al.*, 2017).

Furthermore, the current observation showed no significant change in concentrations of serum urea and creatinine in the treated groups and this is in contrast with previous studies that prove the toxic effect of formalin in urinary system as indicated by elevation in serum urea and creatinine in animals exposed to higher doses of formalin compared with the non-exposed group . (Ramos *et al.*, 2017). Earlier studies on the toxic effect of formalin in liver and kidney tissues on rats orally administered formalin showed prominent histological changes in their liver and kidney tissues. (Mamun, *et al.*, 2014).

Conclusion

- The present study provides an evidence about the abuse of toxic hazardous chemicals such as formalin as milk preservative by local farmers in Khartoum State, and evaluates the toxic effect of formalin on vital organs.
- Adding formalin was common in almost all tested samples.
- The findings is expected to encourage the local farmers and policy makers to find better ways to preserve milk and to impose more strict legislations to prevent such practice

References

- Afrin, M., Amin, T. Karim, R and Islam, M. R, 2016. Effects of formaldehyde intoxication on liver of Swiss albino mice. *IOSR-JAVS.*, 9:76-81.
- B. K. Saha , M.Y. Ali , M. Chakraborty , Z. Islam and A. K. Hira, 2003. Study on the Preservation of Raw Milk with Hydrogen Peroxide (H₂O₂) for Rural Dairy Farmers. *Pakistan Journal of Nutrition.* 2: 36-42 DOI: 10.3923/pjn.2003.36.42
- Beall, J.R., and Ulsamer, A.G, 1984. Formaldehyde and hepatotoxicity. *J Toxicol Environ Health.*, 14: 1-21. DOI: [10.1080/15287398409530560](https://doi.org/10.1080/15287398409530560)
- European Food Safety Authority, 2014. Scientific Opinion on the safety and efficacy of formaldehyde for all animal species based on a dossier submitted by Regal BV1. *EFSA Journal*, 12(2):3561
- Gwin M. C, Lienert G, Kennedy J.I., 2010. Formaldehyde exposure and asthma in children: a systematic review.

- Environ Health Perspect., 118:313–7. doi: 10.1289/ehp.0901143. Epub 2009 Nov 6.
- James, A. Swenberg., Benjamin, C. Moeller, Kun, Lu, Julia, E. Rager, Rebecca, Fry, and Thomas, B. Starr, 2013. Formaldehyde Carcinogenicity Research: 30 Years and Counting for Mode of Action, Epidemiology, and Cancer Risk Assessment. *ToxicolPathol.*, 41: 181–189. <https://doi.org/10.1177/0192623312466459>
- Jeffery, P., Koplán, M.D, 1999. Toxicological Profile for Formaldehyde. Administration agency for toxic substances and disease. July P 9-263
- Kate, S., Carol, K., Muriel, C., MicKate, S. Carol, K. Muriel C., and Michael M, 2009. Milk Matters. Literature Review of Pastoralist Nutrition and Programming Response, P :6-28
- Liu Z., Que S, Xu J, Peng T, 2014. Alanine Aminotransferase-Old Biomarker and New Concept: A Review. *Int J Med Sci*, 11:925-935. doi: [10.7150/ijms.8951](https://doi.org/10.7150/ijms.8951)
- M. A. A. Mamun., M. A. Rahman, M. K. zaman, Z. Ferdousi and M. Abu Reza, 2014. Toxicological effect of formalin as food preservative on kidney and liver tissues in mice model. *IOSR-JESTFT.*, 8: 47-51 DOI: 10.9790/2402-08924751
- Mahmut Cay., Evren Kose., Azibe Yildiz., Osman Ciftci., Nigar Vardi., Sinan Bakirci., Deniz Senol., Songul Cuglan., Zulal Oner and Nihat Ekinci. (2017). The Effect of Chrysin on Liver Damage Induced By Subchronic Toxicity of Formaldehyde in Rats. *AMAJ*, 3: 42-47. DOI: 10.5455/amaj.2017.03.040
- Mahmut, Cay., Evren. Kose, Azibe. Yildiz, Osman. Ciftci, Nigar. Vardi, Sinan. Bakirci, Deniz. Senol, Songul. Cuglan, Zulal. Oner, Nihat. Ekinci, 2017. The Effect of Chrysin on Liver Damage Induced By Subchronic Toxicity of Formaldehyde in Rats. *Original Research*; 3: 42-47. DOI: 10.5455/amaj.2017.03.040
- Mamun, M. A. A., Rahman. M.A, K.zaman. M, Ferdousi. Z, Abu Reza. M, 2014. Toxicological effect of formalin as food preservative on kidney and liver tissues in mice model. *IOSR-JESTFT*; 8:47-51. www.iosrjournals.org
- OlootoW., 2010. Assessment of the effect of formaldehyde exposure on liver of on mortuary worker in south western Nigeria, *Nigerian Medical Practitioner*. V57, DOI: 10.4314/nmp.v57i4.57942
- Pehrsson, P.R., Haytowitz, D.B., Holden, J.M., Perry, C.R. and Beckler, D.G, 2000. *Journal of Food Composition and Analysis.*, 13:379-389. doi: [10.1016/j.jfca.2007.07.006](https://doi.org/10.1016/j.jfca.2007.07.006)
- Ramos, C.O., Nardeli, C.R, Campos, K.K.D, Pena, K.B, Machado, D.F, Bandeira, A.C.B, Costa, G.P, Talvani, A, Bezerra, F.S. , 2017. The exposure to formaldehyde causes renal dysfunction, inflammation and redox imbalance in rats. *Exp ToxicolPathol* 69:367-372. doi: 10.1016/j.etp.2017.02.008.
- Rolf Jost., 2007. Milk and Dairy Products. *Ullmann's Encyclopedia of Industrial Chemistry*. DOI: [10.1002/14356007.a16_589.pub3](https://doi.org/10.1002/14356007.a16_589.pub3)
- Sadyekum., Mustafa Sandikci., Ulker Eren and Nursal Metin., 2010. Effect of Formaldehyde and Xylene Inhalation on Fatty Liver and Kidney in Adult and Developing Rats. *Journal of animal and Veterinary Advances.*, 9:396-401 DOI: [10.3923/javaa.2010.396.401](https://doi.org/10.3923/javaa.2010.396.401)
- Seškēna1, S., and Jankevic, L, 2007. Influence of chemical preservatives on the quality and composition indices of raw milk samples. *Acta Universitatis Latviensis*, 723:171–180
- Singh, A. Chandra, G, Aggarwal, A. Kumar, 2012. Adulteration Detection in Milk. *Research News for U (RNFU)*, 5: 52-53.
- Snedecor, G.W. and Cochran, W.C, 1989. *statistical method*, 8th end lowa state university press, Ames, Iowa
- Tang X., Bai Y, Duong A, Smith MT, Li L, Zhang L. 2009. Formaldehyde in China: production, consumption, exposure levels, and health effects. *Environ Intl.*, 35:1210–24. doi: 10.1016/j.envint.2009.06.002. Epub 2009 Jul 9.